

# Prevalence of Hip Ultrasound Abnormalities in Newborns With a Hip Click

Clinical Pediatrics  
1–5  
© The Author(s) 2020  
Article reuse guidelines:  
sagepub.com/journals-permissions  
DOI: 10.1177/0009922820920011  
journals.sagepub.com/home/cpj



John T. Gaffney, DO<sup>1</sup>  and John Spellman, MD<sup>2</sup>

## Abstract

A hip click on examination of the newborn hip is believed to be the result of a ligament or myofascial structure and thought to be benign. Some studies suggest a link between hip clicks and developmental dysplasia of the hip. The purpose of our study is to estimate the prevalence of ultrasound hip abnormalities in newborns with a hip click and an otherwise normal physical examination. **Results.** Ninety patients meeting inclusion criteria of a hip click with an otherwise normal physical examination underwent diagnostic ultrasound with a 17.8% prevalence of hip abnormalities found (95% confidence interval  $\pm 7.9\%$  [range of 9.9% to 25.7%]). Our study had 64 (71%) females and 26 (29%) males. The prevalence of hip pathology for females was 18.8% (12 of 64 patients) and for males was 15.4% (4 of 26 patients). Thirty-three patients were found to have bilateral hip clicks on presentation, with 21.2% (7 of 33) of those patients found to have hip pathology on ultrasound (3 of the 7 had pathology of both hips). Six patients had a family history of hip dysplasia and 1 of these patients (16.7%) had pathology on ultrasound. The average age to hip sonography was 6.6 weeks. **Conclusions.** In all, 17.8% of newborns with a hip click were found to have hip abnormalities on ultrasound. The prevalence of hip pathology, on ultrasound, suggests that additional larger, prospective studies are needed to clarify the association between a hip click and abnormal ultrasound found at 6 weeks of age or greater.

## Keywords:

Hip Click, Newborn, Ultrasound, Abnormality, Dysplasia

## Introduction

The orthopedic examination of a newborn includes evaluation of the lower extremity for leg bowing, foot deformities, and hip dysplasia. The hip joint is examined for malformation and instability, which can be evidenced by symmetry of leg lengths, skin folds, range of motion, and performing Ortolani's test and Barlow's maneuver.

Marino Ortolani, an Italian pediatrician, developed a test in 1937 to check for the dislocated hip that can be reduced into the socket (acetabulum). After the age of 6 weeks, this sensation is rarely detectable and should not be confused with snapping that is common and can occur in stable hips when ligaments in and around the hip create clicking noises. When the Ortolani test is positive due to hip dislocation, treatment is recommended to keep the hip in the socket until stability has been established.<sup>1</sup>

T. G. Barlow, an English pediatrician, did further research on the topic of hip instability and devised his

own test during 1957–1962 at Hope Hospital Salford, Manchester, England. The Barlow maneuver identifies a loose hip that can be pushed out of the socket with gentle pressure. Barlow found that  $>60\%$  of newborns with hip instability became stable by age 1 week, and 88% became stable by age 2 months, leaving only 12% (of the 1 in 60 newborns, or 0.2% overall) with residual hip instability.<sup>2</sup>

The literature is divided on the significance of a hip click in a newborn with an otherwise normal physical examination (patients without gross signs of instability and a negative Ortolani and Barlow). A hip

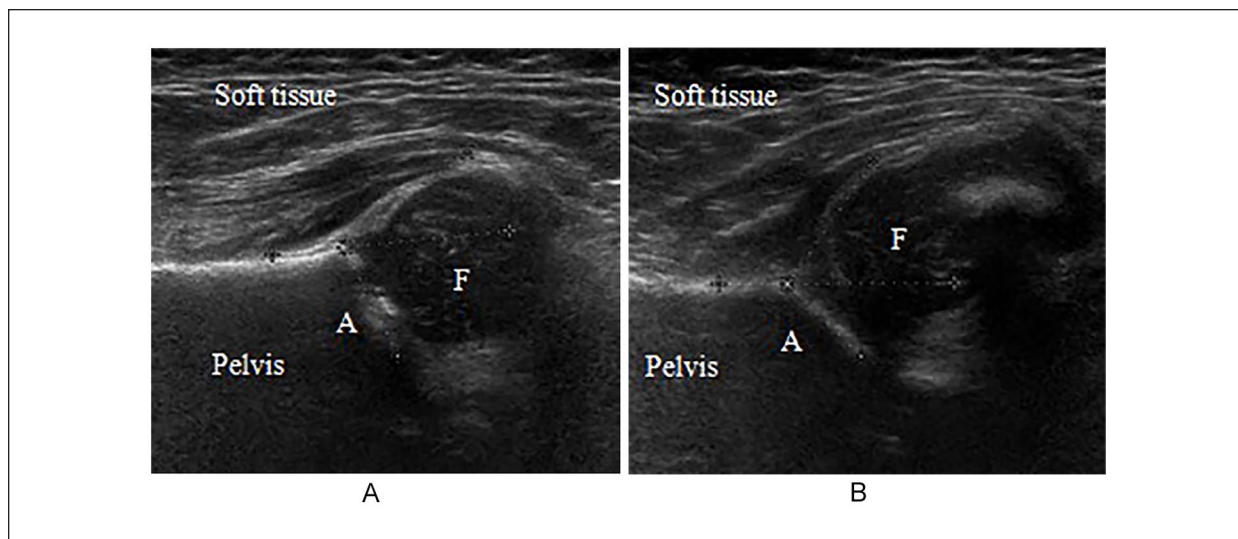
<sup>1</sup>NYU Winthrop Hospital, Garden City, NY, USA

<sup>2</sup>Stony Brook University Hospital, Stony Brook, NY, USA

## Corresponding Author:

John T. Gaffney, NYU Winthrop Hospital, 1300 Franklin Avenue, Suite UL 3B, Garden City, NY 11530, USA.

Email: gaffney@att.net



**Figure 1.** (A) Normal study of neonate at 6 weeks. Alpha angle measures  $69.9^\circ$  and  $\beta$  angle is  $34^\circ$ . (B) Abnormal hip sonogram demonstrating a dislocated hip and shallow acetabulum. Alpha angle measures  $44^\circ$  and  $\beta$  angle is  $54^\circ$ . A, acetabulum; F, femoral head.

click found on a newborn examination has traditionally been thought to be a benign process caused by a ligament or myofascial structure.<sup>3</sup> Some studies provide evidence in favor of this thought, while others have shown results that implicate a hip click as a potential risk factor for developmental dysplasia of the hip (DDH).

Hip dysplasia, having an unknown etiology, uses the predictive factors of breech presentation, positive family history, and female gender to help determine the need for further diagnostic testing. Hip dysplasia signifies an abnormality in the size, shape, orientation, or organization of the femoral head, acetabulum, or both. With DDH, it was found that 60% of the time the left hip was affected, 20% in the right hip and 20% bilaterally.<sup>4</sup> The long-term effects of undiagnosed DDH are hip deformity, gait disturbance, premature arthritis, and potential joint replacement surgery.<sup>5</sup>

The clinical significance of a hip click in the newborn has long been debated in the literature. Some studies found that hip clicks represent structural abnormalities, causing hip instability and increasing the risk for DDH. Cunningham et al<sup>6</sup> studied 7864 infants, finding 622 (7.9%) with “minor hip signs” (clicking or grating of hip). This subset underwent clinical and radiographic evaluation at 4 months, where 34 had serious pathology. The resulting study recommendations were for systematic follow-up and radiographic examination at 4 to 6 months of age.

The study by Jones<sup>7</sup> examined 3289 neonates over 1 year and found 426 (12%) to have DDH. This study established hip clicks as a risk factor for DDH.

There are also investigators who believe that hip clicks are primarily a benign soft tissue snapping that resolves over the normal course of development without need for intervention and no increased risk for DDH. The study by Bond et al<sup>3</sup> examined 50 neonates with a hip click and no other risk factors. When later evaluated at 3 months with ultrasound, no hip abnormalities were detected, concluding that soft tissue hip clicks were not abnormal and did not represent instability in these infants.

Kamath and Bramley<sup>8</sup> conducted a study that evaluated 176 babies with isolated clicky hips and no other risk factors. The reevaluation at 6 weeks revealed 7 babies with abnormal ultrasound of the hip. The 6-month follow-up demonstrated normal hips for all participants. The conclusion from this study was that isolated hip clicks at 6 weeks of age without other risk factors is not a prognostic predictor of DDH.

The study by Terjesen et al<sup>9</sup> also found that most newborn infants with abnormal and suspicious ultrasound findings, and a normal clinical examination will have hips that settle spontaneously, not requiring treatment.

Our study is designed to investigate if a hip click in a newborn is truly a benign process, or if there is a subset of the population that has true hip pathology. This retrospective chart study was designed to estimate the prevalence of hip pathology in this patient population utilizing ultrasound evaluation.

## Methods

The institutional review board approved this study. Charts of all patients evaluated by the senior author for

a hip click between March 2007 and September 2011 were reviewed. Of the 250 charts reviewed, 90 patients met inclusion criteria for our study, which included a diagnosis of hip click and an ultrasound evaluation of the hips. The other 160 patients fell under our exclusion criteria, which included a positive Ortolani or Barlow test (these patients were treated for developmental hip dysplasia without an ultrasound) or use of other diagnostic tests. Children who presented at older ages received X-rays, instead of ultrasound, to evaluate for hip pathology and were excluded. Also excluded were patients lost to follow-up and not receiving an ultrasound, as well as those where the diagnosis was other than hip click (eg, asymmetric folds, breech presentation, and abnormal hip range of motion).

Our study had 64 (71%) females and 26 (29%) males. The prevalence of hip pathology, on ultrasound, for females was 18.8% (12 of 64 patients) and for males was 15.4% (4 of 26 patients). Bilateral hip clicks were present on 33 patients with 7 (21.2%) found to have hip pathology on ultrasound (3 of the 7 had pathology of both hips).

The patients included in the study underwent diagnostic hip ultrasounds following their diagnosis of a hip click. Static and dynamic hip testing was done on all patients in the study (Figure 1). Static ultrasound visualizes the anatomy, allowing for measurement of Graf  $\alpha$  and  $\beta$  angles. Dynamic ultrasound places stress on the hip joint and the motion is observed on a monitor. The Graf  $\alpha$  angle is formed by the acetabular roof to the vertical cortex of the ilium. The normal value is  $\geq 60^\circ$ . Less than  $60^\circ$  suggests dysplasia of the acetabulum. The Graf  $\beta$  angle is the angle formed between the vertical cortex of the ilium and the triangular labral fibrocartilage (echogenic triangle). There is a great deal of variability in the  $\beta$  angle (much more than the  $\alpha$  angle).

The sonograms were evaluated by 3 fellowship-trained radiologists (NYU Winthrop University Hospital) and 1 fellowship-trained pediatric orthopedist. The prevalence of abnormalities present on ultrasound was then recorded. Abnormalities on ultrasound included abnormal measured Graf  $\alpha$  angle or subluxation of either hip.

The data were analyzed using the Fisher's exact test and  $\chi^2$  test to see if sex, the presence of bilateral hip clicks, or family history of DDH were risk factors for hip pathology in this patient population. Wilcoxon rank sum test and Kruskal-Wallis test with exact  $P$  values were used to compare if there was difference in age at first sonogram across different groups.

## Results

The prevalence of hip pathology (subluxation or dislocation) on ultrasound for newborns with a hip click in

our study was 17.8% (16 of 90 patients; 95% confidence interval =  $\pm 7.9\%$  [range of 9.9% to 25.7%]). Our study had 64 (71%) females and 26 (29%) males. The prevalence of hip pathology for females was 18.8% (12 of 64 patients) and for males was 15.4% (4 of 26 patients). There is a slightly higher prevalence in our female patients, however, this was not statistically significant ( $P = 1$ ).

Bilateral hip clicks were present on 33 patients, 7 (21.2%) patients were found to have hip pathology on ultrasound (3 of the 7 had pathology of both hips). This was slightly higher than the prevalence for the unilateral hip click group; however, it holds no statistical significance ( $P = .15$ ).

Family history of DDH was also investigated as a possible risk factor for hip pathology in newborns with a hip click. A positive family history was present for 6 patients and 1 of these patients (16.7%) was found to have pathology on ultrasound. Again, this has no statistical significance as a risk factor for hip pathology ( $P = 1$ ).

The age of the patient at the time of their first diagnostic ultrasound was also analyzed. The overall average age at first ultrasound was 6.6 weeks (range = 1-14 weeks). For the patients with normal sonographic findings, the average age was 6.7 weeks (range = 2-14 weeks), and the average age for patients with abnormal sonographic findings was 5.1 weeks (range = 1-13 weeks). This difference was found to be statistically significant with a  $P$  value of .0089.

## Discussion

Traditionally, a hip click found on physical examination of the newborn has been thought to be a benign process that results from snapping of a ligament or myofascial structure around the hip or knee.<sup>6</sup> Several structures have been proposed as potential culprits. Intra-capsular structures include ligamentum teres, labrum, and pulvinar, while some of the extra-capsular structures include the iliopsoas tendon, tensor fascia, or a referred click from the knee.<sup>3</sup> These hip clicks have a reported incidence of around 10% in newborns.<sup>3,7</sup> Most hip clicks have been shown to resolve in  $<1$  year.<sup>3</sup>

The presence of a hip click does not diagnose hip dysplasia, and most newborns with a hip click have normal hips. However, the absence of clinical signs and medical history is not a guarantee of normal hips.<sup>10</sup> A combination of physical examination, ultrasound, and X-rays are normally needed to diagnosis hip dysplasia or to ensure normal development of the hip.<sup>11</sup>

Hip clicks have been described as a risk factor for development of DDH because a subset of newborns

with a hip click was diagnosed with DDH. It has been recommended that any infant with a hip click should be followed systematically over the first year for any sign of hip instability.<sup>3,8</sup> It has been recommended to perform a follow-up X-ray at 4 to 6 months of age in the newborn with a hip click.<sup>6</sup>

Ultrasound examination of the newborn is safe, reliable, and avoids radiation.<sup>3</sup> Ultrasound is used to visualize the femoral heads, prior to ossification, in the newborn. This procedure has been used for evaluating the hip's cartilaginous components of the acetabulum and proximal femur since the early 1980s.<sup>12</sup>

With the high sensitivity and specificity of ultrasound, one study reported finding 20.8% of neonates with possible dysplastic hips with a clinically normal examination.<sup>13</sup>

Ultrasound is also used to monitor DDH, while the neonate is in the Pavlik harness for DDH treatment.<sup>12</sup>

The long-term concern is the importance of the hip click and its relevance for developing into a more serious and chronic condition. The American Academy of Pediatrics Subcommittee on DDH has estimated that approximately 15% of DDH (instability or dislocation) is not detectable at birth. The late presentation of DDH, premature arthritis of the hip secondary to developmental subluxation, and acetabular dysplasia can be prevented through repeated early detection during the first year of life.<sup>14</sup>

Our study found a prevalence of hip pathology detected on ultrasound to be 17.8% in neonates with a hip click and an otherwise normal hip examination. The patients in our study with pathologic hip findings underwent treatment in a Pavlik harness and after treatment, all were found to have normal development of their hips on follow-up. These results suggest that there may be a subgroup of this patient population that does have treatable hip pathology.

We also evaluated several potential DDH risk factors to determine if any of them had a statistically significant increased association with hip pathology. We evaluated the patient's gender, the evidence of bilateral hip click, and family history of DDH and found that none of them were risk factors for hip pathology.

Currently, ultrasound is commonly used for the diagnosis of early stage instability or subluxation, in the newborn, when a hip click is present. We can avoid underdiagnosing (silent hip dysplasia) or overtreating a self-resolving hip click if we can better predict those at risk.

Based on the results of our study, additional prospective and larger studies are needed to determine the clinical significance of a hip click in a neonate with an otherwise normal physical examination. All hip clicks should not be treated as a progressive developmental process, but monitored for changes.

This study has several important limitations. This is a retrospective study that evaluated 90 neonates with limited medical history. Visit information and treatment plans could be followed retrospectively as long as included in the medical records. Long-term ultrasound and radiology follow-up was not conducted on all participants. The time to follow-up was highly variable.

### Acknowledgments

We would like to thank the Biostatistical Consulting Core in the Department of Preventative Medicine at Stony Brook University for their help with analysis of the data collected in this project.

### Author Contributions

Both Authors contributed to collecting Data, analyzing data and writing portions of the manuscript.

### Declaration of Conflicting Interests

The author(s) declared no potential conflicts of interest with respect to the research, authorship, and/or publication of this article.

### Funding

The author(s) received no financial support for the research, authorship, and/or publication of this article.

### ORCID iD

John T. Gaffney  <https://orcid.org/0000-0003-2877-4107>

### References

1. International Hip Dysplasia Institute. Infant examination. <http://hipdysplasia.org/for-physicians/pediatricians-and-primary-care-providers/infant-examination/>. Accessed April 4, 2020.
2. Barlow TG. Early diagnosis and treatment of congenital dislocation of the hip. *J Bone Jt Surg Br.* 1962;44-B:292-301
3. Bond CD, Hennrikus WL, DellaMaggiore ED. Prospective evaluation of newborn soft-tissue hip "clicks" with ultrasound. *J Pediatr Orthop.* 1997;17:199-201.
4. Storer SK, Skaggs DL. Developmental dysplasia of the hip. *Am Fam Physician.* 2006;74:1310-1316.
5. Shorter D, Hong T, Osborn DA. Cochrane review: Screening programmes for developmental dysplasia of the hip in newborn infants. *Evid Based Child Health.* 2013;8:11-54.
6. Cunningham KT, Moulton A, Beningfield SA, Maddock CR. A clicking hip in a newborn baby should never be ignored. *Lancet.* 1984;1:668-670.
7. Jones DA. Importance of the clicking hip in screening for congenital dislocation of the hip. *Lancet.* 1989;1:599-601.

8. Kamath S, Bramley D. Is “clicky hip” a risk factor in developmental dysplasia of the hip? *Scott Med J*. 2005;50:56-58.
9. Terjesen T, Holen KJ, Tegnander A. Hip abnormalities detected by ultrasound in clinically normal newborn infants. *J Bone Joint Surg Br*. 1996;78:636-640.
10. De Pellegrin M. Ultrasound screening for congenital dislocation of the hip. Results and correlations between clinical and ultrasound findings. *Ital J Orthop Traumatol*. 1991;17:547-553.
11. International Hip Dysplasia Institute. Infant and child developmental dysplasia of the hip. <http://hipdysplasia.org/developmental-dysplasia-of-the-hip/>. Accessed April 4, 2020.
12. Smergel E, Losik SB, Rosenberg HK. Sonography of hip dysplasia. *Ultrasound Q*. 2004;20:201-216.
13. Castelein RM, Sauter AJ, de Vlioger M, van Linge B. Natural history of ultrasound hip abnormalities in clinically normal newborns. *J Pediatr Orthop*. 1992;12:423-427.
14. Cady RB. Developmental dysplasia of the hip: definition, recognition, and prevention of late sequelae. *Pediatr Ann*. 2006;35:92-101.