


Functional Improvements of Speech, Feeding, and Sleep After Lingual Frenectomy Tongue-Tie Release: A Prospective Cohort Study

Clinical Pediatrics
1–8
© The Author(s) 2020
Article reuse guidelines:
sagepub.com/journals-permissions
DOI: 10.1177/0009922820928055
journals.sagepub.com/home/cpj


Richard Baxter, DMD, MS¹ , Robyn Merkel-Walsh, MA, CCC-SLP/COM^{2,3},
Barbara Stark Baxter, MD, FACP⁴, Ashley Lashley, BS¹,
and Nicholas R. Rendell, MSc, PhD⁵

Abstract

Recent studies suggest that speech, solid feeding, and sleep difficulties may be linked to restricted tongue function. Children with tongue restrictions and speech, feeding, and sleep issues underwent lingual frenectomies with a CO₂ laser, paired with myofunctional exercises. Questionnaires were completed before, 1 week after, and 1 month following treatment. Thirty-seven patients participated in the study (mean age 4.2 years [range 13 months to 12 years]). Overall, speech improved in 89%, solid feeding improved in 83%, and sleep improved in 83% of patients as reported by parents. Fifty percent (8/16) of speech-delayed children said new words after the procedure ($P = .008$), 76% (16/21) of slow eaters ate more rapidly ($P < .001$), and 72% (23/32) of restless sleepers slept less restlessly ($P < .001$). After tongue-tie releases paired with exercises, most children experience functional improvements in speech, feeding, and sleep. Providers should screen for oral restrictions in children and refer for treatment when functions are impaired.

Keywords

tongue-tie, ankyloglossia, frenectomy, frenotomy, feeding, speech, sleep-disordered breathing

Introduction

Historically, tongue-ties (ankyloglossia) were associated with speech clarity issues; hence, the term “tongue-tied” to describe those with poor speech intelligibility. Messner and Lalakea saw improvement after release in 9 of 11 tongue-tied patients (82%) with speech difficulties.¹ Later, Walls et al evaluated 71 children treated at birth for tongue-ties and found their speech better than children who were left untreated and similar to controls who never had ties.² They concluded that there is a long-term benefit for speech after tongue-tie release in a newborn.² Ito et al studied articulation in 5 children before and after frenotomy and found that substitution and omission resolved early after tongue-tie release, but speech distortion took longer to improve.³ Baxter and Hughes reported 5 cases of children treated for posterior tongue-tie and found that speech and progression in speech therapy improved.⁴ Last, Daggumati treated 48 children and found that those with moderate speech impairment benefited more than those with mild impairment.⁵

Most tongue-tie research focuses on breastfeeding, with several randomized controlled trials and other studies demonstrating benefit to the nursing dyad.^{6–11} Solid feeding issues were not reported to occur with tongue-ties until a 2018 case series linking 5 children with posterior tongue restrictions to feeding difficulties.⁴ All 5 saw resolution of feeding struggles after proper releases.⁴ Feeding difficulties include increased oral transit time, decreased bolus mobility, choking, gagging, expelling food, frustration with eating, diet selectivity, pocketing food, and tongue thrusting.^{12,13} Recently, a 21-month-old

¹Alabama Tongue-Tie Center, Pelham, AL, USA

²TalkTools, Charleston, SC, USA

³Ridgefield Board of Education, Ridgefield, NJ, USA

⁴Allergy and Asthma Preston Center, Dallas, TX, USA

⁵University of London, London, UK

Corresponding Author:

Richard Baxter, Alabama Tongue-Tie Center, 2480 Pelham Pkwy, Pelham, AL 35124, USA.

Email: info@TongueTieAL.com

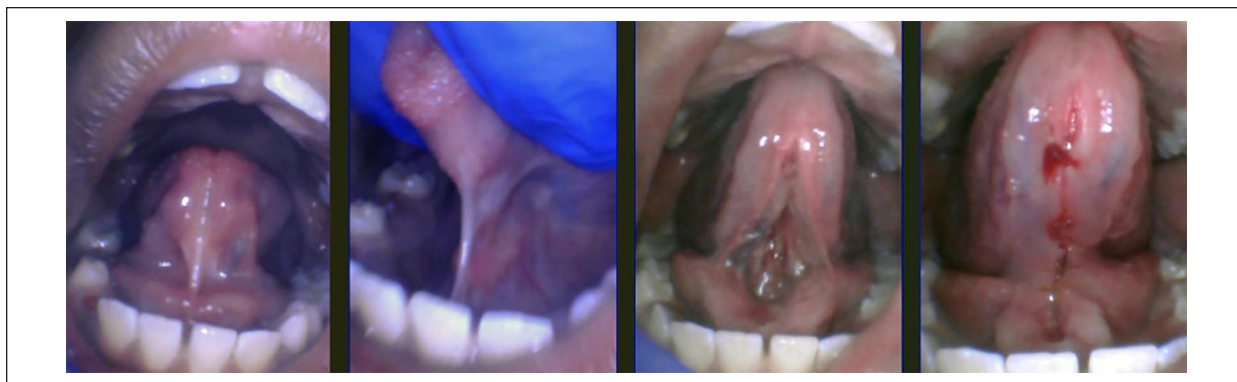

Figure 1. Example of partial versus full release. An 11-year-old child with a tongue restriction (not part of the study) was incompletely released under general anesthesia at age 8 and had persistent speech and sleep difficulty. Notice the impaired function and lift of the tongue (left) and restricted tissue with digital elevation preoperatively (middle left). After a full CO₂ laser release with no bleeding, he can elevate his tongue to the palate (middle right) and final sutured closed result (right).

child with posterior tongue-tie, significant dysphagia, and aspiration improved significantly after release, as imaged by videofluoroscopic swallow study.¹⁴

Ankyloglossia has been linked to sleep difficulties and sleep apnea in children and adults.¹⁵⁻¹⁷ A tongue-tie prevents the tongue from resting on the palate. This lack of tongue to palate suction, especially during sleep, allows the tongue to fall into the pharynx at night and restrict or obstruct the airway and leads to sleep-disordered breathing or sleep apnea.^{17,18} In a recent systematic review, myofunctional therapy was shown to retrain the tongue to properly rest on the palate and prevent it from occluding the airway.¹⁹ Children achieved a 62% decrease in the apnea-hypopnea index (AHI), and adults attained a 50% decrease in the AHI.¹⁹ Myofunctional therapy often can help but is sometimes limited by inadequate tongue mobility.¹⁷

Speech, feeding, and sleep significantly affect a child's and family's quality of life in the early years. We sought to investigate the effects of complete frenectomies combined with myofunctional therapy on the lives of children and families. Many studies of tongue-ties in infants and children utilize partial frenotomies, or snipping connective tissue with scissors. This method of treatment often leaves thick fascia untouched and does not allow the tongue to achieve a full range of motion and function (Figure 1).²⁰ We utilized a 10 600 nm CO₂ laser (LightScalpel LLC, Bothell, WA) to perform all releases, ensuring a full and functional release of fascia, as well as recommending postoperative myofunctional exercises and active wound management to minimize reattachment. This study was carried out prospectively in a continuous fashion with institutional review board (IRB) approval from Solutions IRB # 2018/12/8.

Methods

Design

This was a prospectively collected, within-participants design utilizing surveys completed at baseline, 1-week postoperatively, and 1-month postoperatively.

Participants

Thirty-seven children who met inclusion criteria were recruited from the Alabama Tongue-Tie Center outpatient specialty clinic. English-speaking children with speech, feeding, and sleep issues aged 13 months to 13 years were eligible for the study. After an initial consultation, informed consent to participate in the study was obtained before the procedure. The study consisted of a preoperative assessment, treatment of the tongue-tie, 1-week in-person follow-up, and 1-month in-person or phone follow-up. Participants were enrolled from December 2018 through June 2019.

Materials

Parents completed a preoperative survey of common symptoms suspected to be related to tongue-ties. The survey comprised 4 domains of speech, feeding, sleep, and other related symptoms reported on a yes/no basis. At 1 week and 1 month after the procedure, the parents were asked to accurately record any changes, positive or negative, on a follow-up survey, which was the reverse of the initial survey and included 4 Likert-type scale questions about overall change (improved/worsened speech, feeding, or sleep) as well as "looking back" whether they would go through the procedure again. The data were analyzed using SPSS Version 25. Descriptive

Table 1. One Week and 1 Month Overall Improvements.

One week			
Answer	Speech, N = 30, % (n)	Feeding, N = 33, % (n)	Sleep, N = 35, % (n)
Significantly worse	0 (0)	0 (0)	0 (0)
Somewhat worse	0 (0)	3.0 (1)	2.9 (1)
No change	23.3 (7)	27.3 (9)	11.4 (4)
Somewhat better	43.3 (13)	45.5 (15)	48.6 (17)
Significantly better	33.3 (10)	24.2 (8)	37.1 (13)
One month			
Answer	Speech, N = 28, % (n)	Feeding, N = 30, % (n)	Sleep, N = 30, % (n)
Significantly worse	3.6 (1)	0	3.3 (1)
Somewhat worse	0	3.3 (1)	6.7 (2)
No change	7.1 (2)	13.3 (4)	6.7 (2)
Somewhat better	39.3 (11)	46.7 (14)	26.67 (8)
Significantly better	50.0 (14)	36.7 (11)	56.7 (17)

statistics, independent *t* test, and a sign test were used to analyze the data.

Treatment Protocol

The consultation visit included an in-depth history utilizing the assessment sheet, as well as a careful examination of the oral cavity. The Kotlow rating scale was used to assess the degree of restriction.²¹ A diagnosis of symptomatic tongue restriction was required for participation. Some patients also had restricted maxillary frenum causing difficulty with oral hygiene. A compounded topical anesthetic was applied to the surgical sites, and 2% lidocaine with 1:100 000 epinephrine was injected if cooperative. Nitrous oxide, oral sedation, and general anesthesia were not required.

The treatment consisted of removing the frenum at 2 W, 29 Hz, 72.5% duty Non-SuperPulse with the 10 600 nm LightScalpel CO₂ laser in a horizontal fashion beginning in the middle of the frenum. The release continued until all fascia and tension of the mucosa were removed, and a diamond shape was evident. The genioglossus muscle was visualized but left undisturbed and minimal to no bleeding occurred in all cases. The average lasing time was 15 seconds. Postoperatively, pain was managed with acetaminophen or ibuprofen. Manual stretching of the wound 2 to 3 times daily as tolerated by the child was recommended. Myofunctional exercises were recommended if the child was able to follow commands.

The patients returned for a 1-week follow-up to assess wound healing, manually stretch the wound to ensure no reattachment, and assess symptom improvement. The patients also returned or completed a phone survey at 1 month.

Results

Parents of all 37 children enrolled completed the 1-week follow-up questionnaire. Thirty parents of study children completed the 1-month questionnaire; 7 were lost to follow-up. The mean age was 4.2 years (range 13 months to 12 years), and 62% of participants (23/37) were male. For each item in the questionnaire, parents marked whether symptoms improved, worsened, or did not change. Many participants noticed an improvement in symptoms not previously recognized or reported. The results are summarized in Tables 1 to 5.

At 1 week, 76% of parents reported improved speech, 69% noticed improved feeding, and 85% observed improved sleep in their children (Table 1). At 1 month, 89% of parents reported improved speech, 83% noted improved feeding, and 83% witnessed improved sleep. One child's parents reported somewhat worse feeding and sleep at 1 week. At 1 month, significantly worse speech and sleep were stated concerning 1 child, another parent reported somewhat worse feeding in her child, and 2 parents observed somewhat worse sleep quality in their children.

Significant improvements in children's speech were reported (Table 2). There was less frustration with communication ($P < .001$). It was easier for parents ($P = .001$) and others ($P < .001$) to understand the children. It was easier for the children to speak quickly ($P = .004$), get words out ($P < .002$), and make previously difficult sounds ($P < .001$). Speech-delayed children produced new words ($P = .008$), children mumbled less ($P = .008$) and used less baby talk ($P = .031$). Parents also reported positive feeding changes (Table 3) as children ate more rapidly ($P < .001$), exhibited less grazing behavior

Table 2. Speech Improvements Reported at 1 Week or 1 Month.

Item	N	Problem indicated	Improvement indicated ^a	Total improvements ^b	P
Frustration with communication	37	18	15	21	<.001**
Difficult for parents to understand	37	16	11	24	.001**
Difficult for outsiders to understand	37	24	15	22	<.001**
Difficulty speaking fast	37	16	9	16	.004**
Difficulty getting words out	37	17	10	18	<.002**
Trouble with sounds	37	21	12	17	<.001**
Speech delay	37	16	8	13	.008**
Stuttering	37	4	2	10	.500
Mumbling or speaking softly	37	12	8	13	.008**
Baby talk	37	15	6	11	.031*

^aRelates to individuals who had previously reported an issue.

^bRelates to individuals who reported an improvement without reporting the problem initially.

**Significant at 1%.

Table 3. Feeding Improvements Reported at 1 Week or 1 Month.

Item	N	Problem indicated	Improvement indicated ^a	Total improvements ^b	P
Frustration when eating	37	4	3	18	.250
Difficulty transitioning to solid foods	37	6	3	18	.250
Slow eating/does not finish meals	37	21	16	18	<.001**
Grazing throughout the day	37	21	16	22	<.001**
Packing food in cheeks	37	10	5	13	.063
Picky eater	37	28	10	11	.002**
Choking or gagging on food	37	17	10	16	.002**
Spits out food	37	17	11	17	.001**
Will not try new foods	37	15	4	15	.125

^aRelates to individuals who had previously reported an issue.

^bRelates to individuals who reported an improvement without reporting the problem initially.

**Significant at 1%.

($P < .001$), were less picky ($P = .002$), choked and gagged on food less ($P = .002$), and spit food out less often ($P = .001$). Sleep improved significantly as reported by parents (Table 4). Children were less likely to sleep in strange positions ($P < .001$), or kick and move at night ($P < .001$). They slept more deeply ($P < .001$), woke up less fatigued ($P = .002$), had less tooth grinding ($P = .002$), less mouth breathing ($P < .001$), and less snoring ($P < .001$). Interestingly, additional changes were noted by parents (Table 5) as children reported less neck pain ($P < .031$), fewer headaches ($P = .008$), less gag reflex ($P = .002$), less mouth breathing ($P < .001$), less reflux ($P = .002$), less hyperactivity and inattention ($P < .001$), and less constipation ($P = .004$).

An independent *t*-test was carried out between groups of patients to determine any confounding variables. No significant difference in improvement was seen between groups of children with a posterior tongue-tie ($n = 29$)

versus anterior tie ($n = 8$), or between those who had both lip and tongue tie released simultaneously ($n = 14$), and those with only a tongue-tie release ($n = 23$).

Discussion

The results suggest that speech, solid feeding, and sleep can be affected by a restricted tongue, and releasing a tongue-tie properly combined with oral motor or myofunctional exercises can provide functional and quality of life improvement.

Twenty-five patients had 2 or more symptoms of tongue-tie in infancy, and 8 had 4 or more infant feeding symptoms that were not recognized as being due to a restriction of the tongue, and the patients were left untreated. Difficulties with speech, solid feeding, or sleep ensued within a few years. Early treatment in infancy is best.⁶⁻⁸

Table 4. Sleep Improvements Reported at 1 Week or 1 Month.

Item	N	Problem indicated	Improvement indicated ^a	Total improvements ^b	P
Sleeping in strange positions	37	22	16	20	<.001**
Kicking and moving around at night	37	32	23	28	<.001**
Sleeping more deeply and waking less often	37	22	17	28	<.001**
Wetting the bed	37	7	5	10	.063
Wakes tired and not refreshed	37	21	10	16	.002**
Grinds teeth while sleeping	37	16	10	11	.002**
Sleeping with mouth open	37	26	19	22	<.001**
Snoring	37	24	16	20	<.001**
Gasping for air	37	8	3	11	.250

^aRelates to individuals who had previously reported an issue.

^bRelates to individuals who reported an improvement without reporting the problem initially.

**Significant at 1%.

Table 5. Other Related Improvements as Reported by Parents.

Item	N	Problem indicated	Improvement indicated ^a	Total improvements ^b	P
Neck pain	37	6	3	6	<.031*
Temporomandibular joint pain	37	0	0	2	.500
Headaches	37	5	2	8	.008**
Gag reflex	37	9	5	10	.002**
Mouth breathing	37	14	11	17	<.001**
Reflux	37	11	6	10	.002**
Hyperactivity/attention	37	15	9	14	<.001**
Constipation	37	9	4	9	.004**

^aRelates to individuals who had previously reported an issue.

^bRelates to individuals who reported an improvement without reporting the problem initially.

*Significant at 5%; **significant at 1%.

Most previous speech and tongue-tie studies investigated only articulation. This study took a comprehensive look at common symptoms in tongue-tied children. We found a connection between speech delay and tongue-ties in 8 of 16 patients. Those 8 children said new words after the procedure, most on the day of the procedure and continuing for several days to weeks. Five patients in addition to the 8 reported new words after release but did not mark the issue preoperatively so were not counted in the final statistical number. Similar to slow eating or restless sleep, parents did not realize that there was a problem until they observed improvement (see Tables 2–5). If children do not progress in speech or language therapy, a tongue restriction should be suspected.

Children with solid feeding issues improved regarding choking, slow eating, frustration with eating, and pickiness about textures, especially meat. This study is the first prospective study to report changes in solid feeding after tongue-tie release, and the results demonstrate

that children with dysphagia, difficulty managing a food bolus, and other feeding issues should be evaluated for tongue-ties, which limit posterior tongue elevation and impair swallowing. Many children with primary feeding difficulties suffer from undiagnosed tongue restrictions, and low-risk, minimally invasive laser tongue-tie releases should be considered.

Sleep issues dramatically improved in the patients in this study. After treatment, the tongue is able to rest on the palate instead of resting down near the lower jaw. Many younger children (preschool and younger) instinctively rested their tongues on their palates immediately after the releases, while older grade school children benefited from myofunctional exercises to retrain their tongues to rest in the proper position. All patients were given myofunctional exercises to assist in tongue retraining, but compliance is difficult with younger children. Working with speech therapists trained in oral motor exercises is helpful for children younger than 4 years.

In practice, many parents of patients undergoing a tongue-tie release report symptom improvement in seemingly unrelated issues. These are reported in Table 5, as parents reported that children had less neck pain, headaches, gagging, mouth breathing, reflux, hyperactivity and inattention, and constipation. Explaining all of these connections is beyond the scope of this article, but many of these results could be explained by less restricted head and neck fascia, improved oral rest postures, improved sleep quality, and better ability to chew food.

There was no difference between children who had anterior to-the-tip or close-to the-tip ties versus those who had less visible posterior tongue-ties. The symptoms children present with are more important than appearance when determining the need for a release. With minimal appearance of a tie but many tongue-tie symptoms, the posterior tongue-tie patients saw the same improvements as those who had anterior, obvious ties. The concept of tongue-ties as a spectrum of restriction allows the provider to understand that some children with visible ties may be able to function well as they adapt or compensate without a procedure.⁴ Others with minimal appearance have many symptoms and are unable to compensate, indicating that the fascia underlying the frenum is too restrictive and warrants a release.

Tongue elevation, not protrusion, is the critical movement for speech, feeding, and sleep, and releasing the restriction so elevation normalizes is the reason children see improvement. The typical health care practitioner when checking a child's oral cavity says, "Stick out your tongue and say 'Ah.'" One easy change to practice that would allow better identification of a restricted tongue is asking the child (or adult) to lift the tongue. If this task is not possible due to poor volitional control, the examiner can manually check elevation digitally with both index fingers coming from behind the patient. The tongue should elevate most of the way to the palate to the spot behind the incisors with the mouth open normally.²² If the tongue lifts 50% or less, it is significantly restricted and the patient should be assessed for symptoms.²² Refer for treatment if symptomatic. Some children and adults can lift greater than 50% but still have symptoms. Symptoms are more important than appearance. Some children had lip-tie releases at the same time due to difficulties with oral hygiene, or large diastemas between the teeth. There was no difference in improvement noted between the children who had lip- and tongue-ties released versus those who had only tongue releases, indicating that the tongue is the major factor for symptom improvement in speech, feeding, and sleep.

These results are dependent on proper release techniques and on maintaining the wounds with proper stretching and oral motor and myofunctional exercises

to achieve the greatest range of motion and normal function. A proper release can certainly be performed with scissors, but a CO₂ laser provides a clear surgical field to easily remove all restricted fascia. Not all lasers are the same, as a diode laser utilizes a heated quartz tip to remove tissue thermally (at around 1000 °C, similar to cautery), whereas the CO₂ laser removes tissue without contacting the tissue and optically vaporizes (100 °C) the tissue.^{23,24} A CO₂ laser release is not a deep release as some warn against,²⁵ but rather allows the surgeon to precisely remove the mucosa and thick webbing of fascia underneath the frenum layer by layer. This method allows a complete dissection and avoids any structures that should be left undisturbed such as the lingual nerve, submandibular ducts, deep lingual vein, and the genioglossus muscle. The result is a bloodless diamond shape, often only a millimeter or two deep, without tension, that allows full elevation of the tongue.

A minimum of 1 follow-up visit is critical to check healing and guide the family on proper stretching techniques. A team approach working closely with a speech-language pathologist or dental hygienist who utilizes oral motor and/or myofunctional therapy will enhance the likelihood of long-term benefits because neuromuscular reeducation, swallowing, and resting posture benefit from their professional guidance. Most patients in this study had speech therapy but did not have a therapist trained in myofunctional therapy, so oral motor and myofunctional exercises were given to each patient. The patients in this study saw results in many cases the same or next day, indicating the release was the precipitating factor for the observed improvement, but the stretching was critical to ensure that the patient retained the newfound freedom, and exercises were important to reeducate the muscles of the tongue and oral cavity to achieve long-term symptom improvement. At 1 week, most patients had some regrowth of the frenum, and a stretch was performed to reopen the restricted area to help prevent reattachment.

One patient reported significantly worse feeding and sleep at 1 month, and a few were unsure if they would do the procedure again. The procedure is not 100% effective, and that patient did not follow-up after 1 week and, to our knowledge, did not work with a therapist after the procedure. With proper case selection, a team approach to care, proper follow-up, and exercise protocol, negative outcomes can be minimized.

These results should encourage health care professionals treating children suffering from speech, feeding, and sleep trouble to evaluate for tongue restrictions, and consider releases if these commonly associated symptoms are present, regardless of the degree of visible restriction. If children have symptoms in multiple

domains and especially with a history of feeding issues in infancy, a low-risk, in-office procedure along with proper therapy should be considered.

Limitations

Speech and feeding assessments before and after treatment relied on parental reports, which although prone to bias, have been shown to be reliable in other studies.²⁶ Validated instruments for these assessments would help research in this area. There was no control group to compare the results achieved afterward, but most of the improvements in sleep, feeding, or speech were reported by the parents the same day or within a few days of release. Generalizability of results could be affected if the procedure does not fully release the mucosa and fascia, exercises and stretches are not performed, and follow-up is not monitored.

Conclusion

1. This study demonstrates that CO₂ laser tongue-tie releases can yield significant functional improvements in speech, solid feeding, and sleep of children, as reported by parents.
2. The best outcomes were achieved in patients with full releases of restricted fascia as well as a team approach incorporating therapy.
3. Health care providers should check for restrictions to determine if speech, feeding, or sleep difficulties might be related to limitations in tongue movement.
4. Individualized care plans with therapists trained in oral motor and myofunctional therapy are helpful.

Acknowledgments

The authors would like to acknowledge Soroush Zaghi, MD, in assisting with study design.

Author Contributions

All authors were involved in the design, analysis, and/or interpretation of data, drafting the article, or revised it critically, and approved the final manuscript.

Declaration of Conflicting Interests

The author(s) declared no potential conflicts of interest with respect to the research, authorship, and/or publication of this article.

Funding

The author(s) received no financial support for the research, authorship, and/or publication of this article.

ORCID iD

Richard Baxter  <https://orcid.org/0000-0002-7468-0040>

References

1. Messner AH, Lalakea ML. The effect of ankyloglossia on speech in children. *Otolaryngol Head Neck Surg.* 2002;127:539-545.
2. Walls A, Pierce M, Wang H, Steehler A, Steehler M, Harley EH Jr. Parental perception of speech and tongue mobility in three-year olds after neonatal frenotomy. *Int J Pediatr Otorhinolaryngol.* 2014;78:128-131.
3. Ito Y, Shimizu T, Nakamura T, Takatama C. Effectiveness of tongue-tie division for speech disorder in children. *Pediatr Int.* 2015;57:222-226.
4. Baxter R, Hughes L. Speech and feeding improvements in children after posterior tongue-tie release: a case series. *Int J Clin Pediatr.* 2018;7:29-35.
5. Daggumati S, Cohn JE, Brennan MJ, Evarts M, McKinnon BJ, Terk AR. Speech and language outcomes in patients with ankyloglossia undergoing frenulectomy: a retrospective pilot study. *OTO Open.* 2019;3:2473974X19826943.
6. Hogan M, Westcott C, Griffiths M. Randomized, controlled trial of division of tongue-tie in infants with feeding problems. *J Paediatr Child Health.* 2005;41:246-250.
7. Berry J, Griffiths M, Westcott C. A double-blind, randomized, controlled trial of tongue-tie division and its immediate effect on breastfeeding. *Breastfeed Med.* 2012;7:189-193.
8. Buryk M, Bloom D, Shope T. Efficacy of neonatal release of ankyloglossia: a randomized trial. *Pediatrics.* 2011;128:280-288.
9. Ghaheri BA, Cole M, Fausel SC, Chuop M, Mace JC. Breastfeeding improvement following tongue-tie and lip-tie release: a prospective cohort study. *Laryngoscope.* 2017;127:1217-1223.
10. O'Callahan C, Macary S, Clemente S. The effects of office-based frenotomy for anterior and posterior ankyloglossia on breastfeeding. *Int J Pediatr Otorhinolaryngol.* 2013;77:827-832.
11. Pransky SM, Lago D, Hong P. Breastfeeding difficulties and oral cavity anomalies: The influence of posterior ankyloglossia and upper-lip ties. *Int J Pediatr Otorhinolaryngol.* 2015;79:1714-1717.
12. Merkel-Walsh R, Overland L. *Functional Assessment and Remediation of TOTs (Tethered Oral Tissues)*. TalkTools; 2018.
13. Bahr D. *Feed Your Baby and Toddler Right: Early Eating and Drinking Skills Encourage the Best Development*. Future Horizons; 2018.
14. Brooks L, Landry A, Deshpande A, Marchica C, Cooley A, Raol N. Posterior tongue tie, base of tongue movement, and pharyngeal dysphagia: what is the connection? *Dysphagia.* 2020;35:129-132. doi:10.1007/s00455-019-10040-x
15. Huang YS, Quo S, Berkowski JA, Guillemineault C. Short lingual frenulum and obstructive sleep apnea in children. *Int J Pediatr Res.* 2015;1:1. Accessed May 4, 2020. <http://>

- orofacialintegrity.com/wp-content/uploads/2015/05/short-ling-frenum-and-sleep-apnea.pdf
16. Guilleminault C, Huseni S, Lo L. A frequent phenotype for paediatric sleep apnoea: short lingual frenulum. *ERJ Open Res.* 2016;2:00043-2016. doi:10.1183/23120541.00043-2016
 17. Zaghi S, Valcu-Pinkerton S, Jabara M, et al. Lingual frenuloplasty with myofunctional therapy: exploring safety and efficacy in 348 cases. *Laryngoscope Investig Otolaryngol.* 2019;4:489-496.
 18. Baxter R, Agarwal R, Musso M, et al. *Tongue-Tied: How a Tiny String Under the Tongue Impacts Nursing, Speech, Feeding, and More.* 1st ed. Alabama Tongue-Tie Center; 2018.
 19. Camacho M, Certal V, Abdullatif J, et al. Myofunctional therapy to treat obstructive sleep apnea: a systematic review and meta-analysis. *Sleep.* 2015;38:669-675.
 20. Ghaheri BA, Cole M, Mace JC. Revision lingual frenotomy improves patient-reported breastfeeding outcomes: a prospective cohort study. *J Hum Lact.* 2018;34:566-574.
 21. Kotlow LA. Ankyloglossia (tongue-tie): a diagnostic and treatment quandary. *Quintessence Int.* 1999;30:259-262.
 22. Yoon A, Zaghi S, Weitzman R, et al. Toward a functional definition of ankyloglossia: validating current grading scales for lingual frenulum length and tongue mobility in 1052 subjects. *Sleep Breath.* 2017;21:767-775.
 23. Romanos GE, Belikov AV, Skrypnik AV, Feldchtein FI, Smirnov MZ, Altshuler GB. Uncovering dental implants using a new thermo-optically powered (TOP) technology with tissue air-cooling. *Lasers Surg Med.* 2015;47:411-420.
 24. Romanos GE. Diode laser soft-tissue surgery: advancements aimed at consistent cutting, improved clinical outcomes. *Compend Contin Educ Dent.* Published November 2013. Accessed June 18, 2018. https://cced.cdeworld.com/courses/20875-Diode_Laser_Soft-Tissue_Surgery:Advancements_Aimed_at_Consistent_Cutting-Improved_Clinical_Outcomes
 25. Mills N, Keough N, Geddes DT, Pransky SM, Mirjalili SA. Defining the anatomy of the neonatal lingual frenulum. *Clin Anat.* 2019;32:824-835.
 26. Stein MA, Mendelsohn J, Obermeyer WH, Amromin J, Benca R. Sleep and behavior problems in school-aged children. *Pediatrics.* 2001;107:E60.